

CASE REPORT

Management of Comminuted Periprosthetic Distal Femur Fracture

Caleb P. Shin, BS¹; Brendan M. Holderread, BS^{1,2}
Davinder S. Mand, MD¹; Robert A. Probe, MD¹

¹Department of Orthopedic Surgery, Baylor Scott & White Health; Temple, TX, USA

²Department of Orthopedic & Sports Medicine, Houston Methodist Hospital; Houston, TX, USA

ABSTRACT

The incidence of distal femur periprosthetic fractures is increasing as the number of patients living with a knee replacement increases. Adding to the numerical increases, this patient population experience increased fall risk and decreasing bone density with advancing age. Currently, surgical options for distal femur periprosthetic fractures consist of retrograde intramedullary nailing (rIMN), locked plating, or joint revision with distal femoral replacement (DFR). We report a case in which the combined use of rIMN and locked plate afforded sufficient stability to allow for prosthetic retention and postoperative mobilization that could not have been realized with either implant alone. Indications for this combined fixation are discussed

Level of Evidence: V; Case report.

Keywords: Periprosthetic fracture; Total knee arthroplasty; Retrograde intramedullary nail.

INTRODUCTION

Projections show the number of Total knee arthroplasties (TKAs) performed each year will surpass 3 million by the year 2030 [1,2]. TKAs are typically performed in patients who are at an increased risk of falls. Independently, age increases the likelihood of a ground-level fall and developing osteopenia and osteoporosis [3]. Therefore, the incidence of periprosthetic fractures of the

knee is reported to occur in proportion to the number of TKAs being performed [4,5].

Patients often present after a ground-level fall and complain of knee pain, swelling or deformity. To guide treatment, radiographic evaluation involves assessment for fracture location, fracture displacement, and femoral component stability [1]. Computed tomography often adds critical information regarding prosthetic fixation, degree of comminution and the amount of distal bone available for fixation. Should implant retention be desirable, traditional options for fixation include retrograde intramedullary nailing (rIMN) or bridging plate fixation [6,7].

Corresponding Author:

Robert A. Probe, MD

Department of Orthopedic Surgery

Baylor Scott & White Health

32401 South 31st St

Temple, TX 76508, USA

e-mail: robert.probe@bswhealth.org

Dual implant fixation is an approach that combines these two methods theorizing that the resultant combined fixation strength crosses a threshold necessary to allow for postoperative mobilization and fracture healing. As the incidence of periprosthetic fractures increases, the authors believe this alternative is worthy of consideration in fractures with a limited amount of distal bone in patients deemed too young for distal femoral replacement.

Case Presentation

A 65-year-old female with a past medical history of sickle cell disease and bilateral total knee arthroplasty presented to the ED with pain, swelling and gross deformity of the left knee after a ground level fall incurred after slipping on ice. Physical exam revealed tenderness to palpation over the left knee, edema, and effusion. Patient was neurovascularly intact with no evidence of

open fracture, abrasion, or laceration. No tenderness to palpation was noted proximally or distally. Radiographs revealed a significantly shortened, comminuted, periprosthetic distal femur fracture that extended from the metaphysis into the diaphysis (Figures 1AB). Computed tomography confirmed these findings in addition to verifying femoral component stability, degree of comminution and relatively small size of distal metaphyseal bone available for fixation (Figures 2A-C). Considering the patients relatively young age and comminution of the fracture distally, the decision was made to proceed with a combined intramedullary and extramedullary approach.

Surgical Technique

Perhaps the most critical portion of this procedure is the preoperative planning. The manufacturer and model of the femoral component should be known and whether

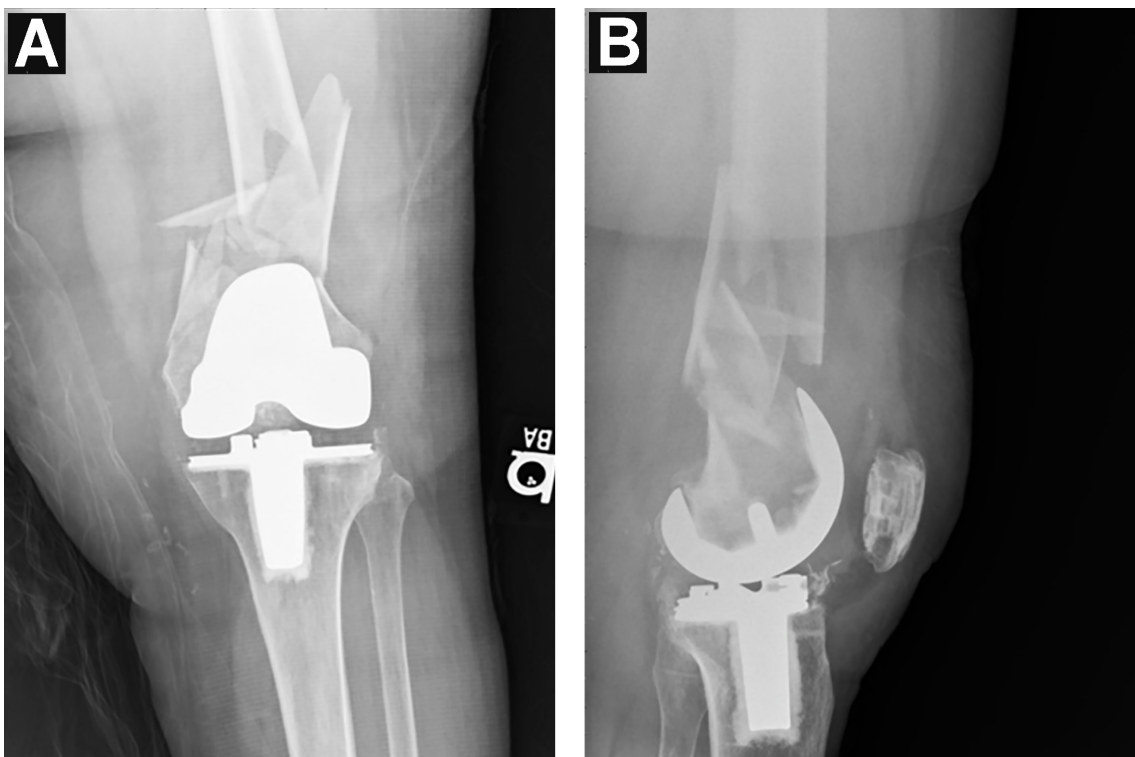


Figure 1. Preoperative anteroposterior (A) and lateral (B) X-rays of the left knee demonstrating comminuted distal femur periprosthetic fracture.

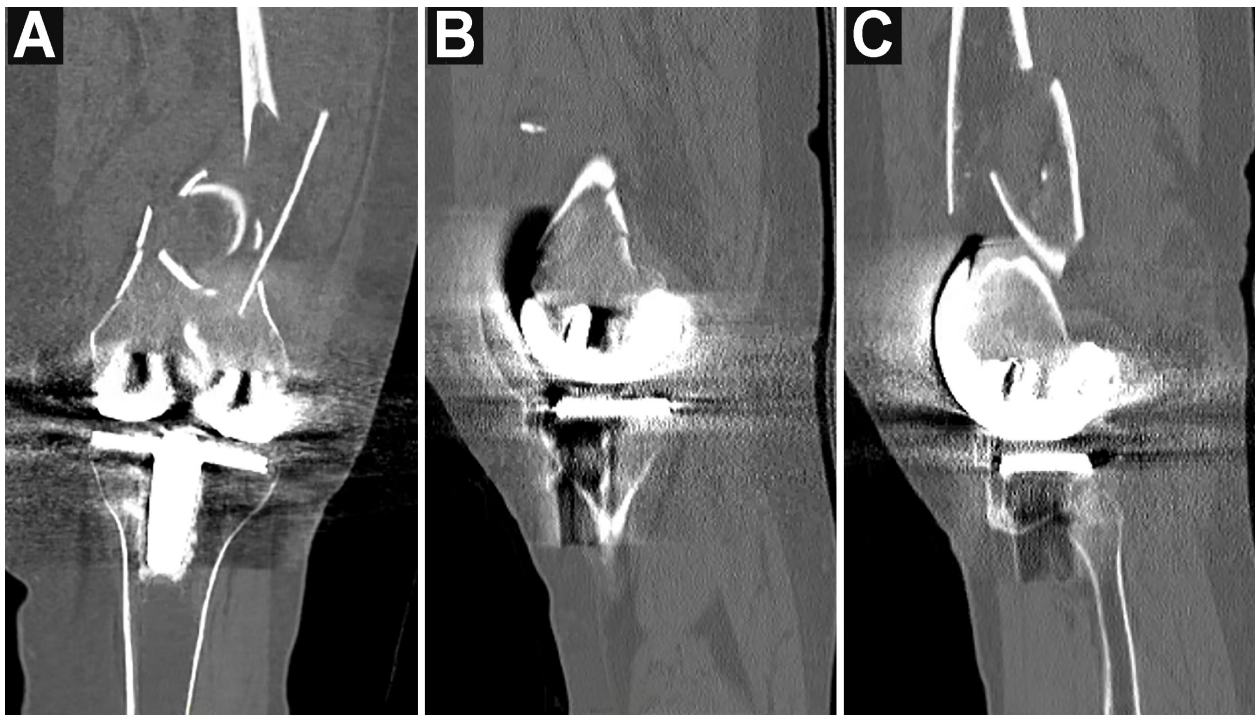


Figure 2. Coronal (A), sagittal medial (B), and sagittal lateral (C) CT of the left knee demonstrating comminuted distal femur periprosthetic fracture.

the implant contains enough absent metal space in the intercondylar zone to allow passage of a retrograde nail [19]. Beyond this, the precise location of the distal interlocking screw holes on the nail and the number of locking screw holes on the plate should be known. This plate should allow placement of variable ankle locking screws that maximize the amount of distal fixation possible. In our case the existing implant had an open box and our selected fixation was the Stryker 11-mm nail and Zimmer periprosthetic lateral locking plate.

Surgery is performed on a radiolucent bed with operative knee placed in 30 degrees of flexion. Reduction is obtained with traction, using a traction table, in a direction that allows restoration of anatomic alignment in the coronal plane. Fine tuning of the sagittal plane reduction is often aided with the strategic placement of bumps beneath posteriorly displaced or angulated segments.

Once reduction is satisfactory, fixa-

tion begins with the retrograde placement of the intramedullary fixation using an infrapatellar approach. Placing this implant as anterior as possible in the box and along the femoral shaft will maximize space available for subsequent screw placement. Utilizing an implant of relatively small diameter will also support this objective. Planning should allow for minimum of two interlocking through the nail and bone solidly affixed to the implant.

The plate is placed through a secondary incision overlying the lateral femoral condyle. Fragments of the lateral condyle are reduced but no attempts are made at reduction of the comminution that lies within the metaphyseal/diaphyseal zone. This zone is bridged by a long plate that is then fixed with a minimum of 3 screws in both proximal and distal segment.

In our case, excellent fixation was achieved with the placement of 3 distal locking screws into the plate (Figures 3AB).

The patient tolerated the procedure well and placed in a soft compressive dressing with toe-touch weight-bearing status. She was switched to a hinged knee brace and instructed on stretching and strengthening exercises at 2 weeks. There were no complications in the immediate postoperative period. By 8-week follow-up, she was partially weight-bearing up to 30 pounds and encouraged to progress to full weight bearing at that time. At 6 months, she was able to walk unassisted, displayed active knee motion from 0 to 100 degrees and resume work.

DISCUSSION

It is estimated that approximately 0.3-2.5%

of patients with primary TKA will sustain a periprosthetic fracture, with close to 300,000 periprosthetic distal femur fractures cited per year, the population at risk is sizable and growing [8]. The total number of TKAs performed each year is increasing and periprosthetic distal femur fractures are important complications following TKA that lack formal algorithm-based management. Each of these injuries brings a unique combination of existing implants, bone quality, fracture geometry, patient demands and/or functional expectations. Treatment selection requires careful consideration of each of these variables, in addition to the performance of the various treatment methods.

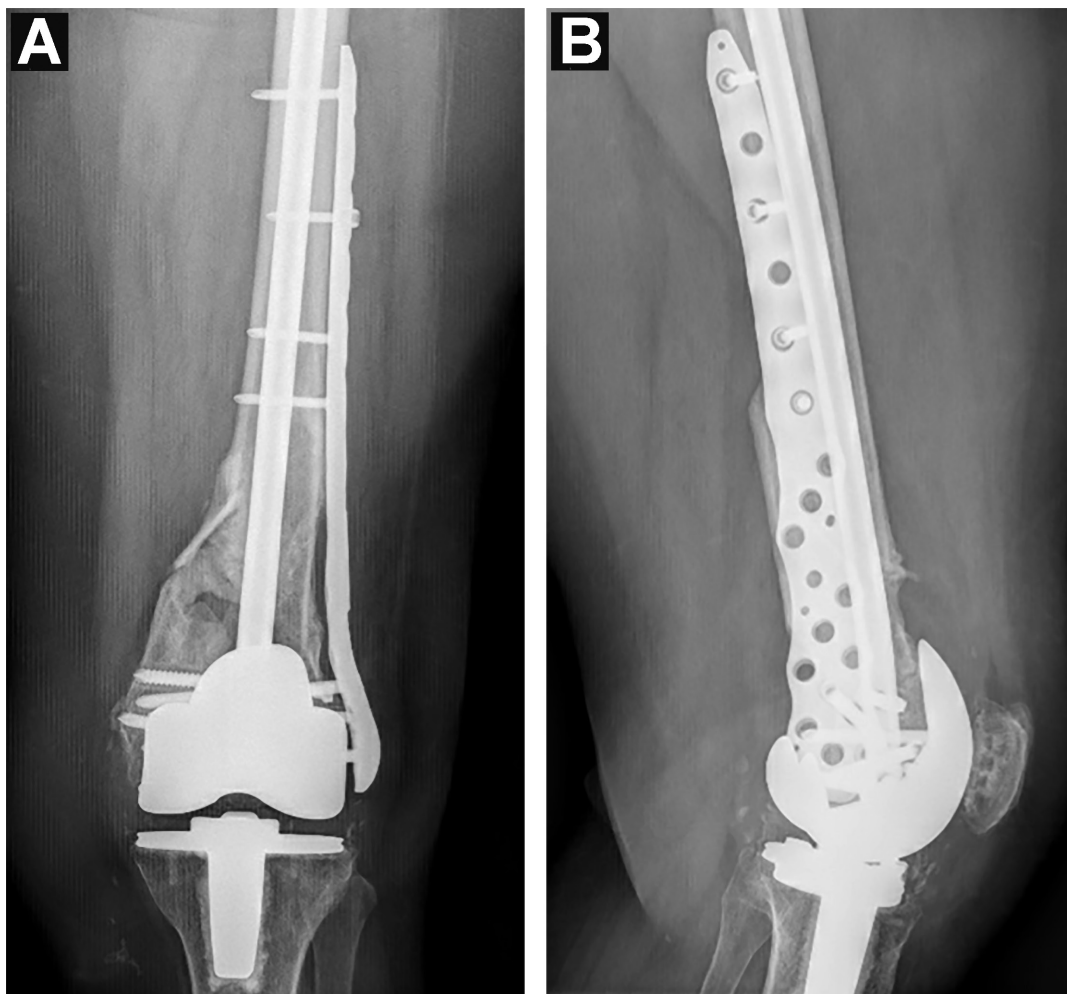


Figure 3. Anteroposterior (A) and lateral (B) X-rays at 6-week post-surgery demonstrating adequate fixation and healing of the periprosthetic femur fracture.

Many would consider retrograde intramedullary nailing as the first treatment option. This approach is favorable because of the procedure's relative ease and the indirect fracture reduction leads to minimal soft-tissue damage and higher reported union rates [8]. Unfortunately, this is not always feasible because of insertion blockage by the femoral component, fracture comminution or limited distal bone for stable fixation.

More comminuted fractures, like ours, can be approached with multiple locking screws and bridge plating. Large diameter locking screws can be used for distal fixation in combination with long plates for proximal fixation [8]. However, lower union rates are common with locked plating. Multiple studies have shown nonunion rates ranging from 15-20% [9]. Periods of prolonged limited weight bearing is also often recommended with these implants. These limitations relegate locked plating as a valuable but not first line method of periprosthetic fracture treatment.

Distal femoral replacement (DFR) was considered and has also shown success in the management of periprosthetic distal femur fractures in the elderly population [10]. DFR has been reported to show subjective patient satisfaction with early full-weight bearing status [9]. Furthermore, there is no risk of nonunion as there is no fracture to heal [9]. DFR provides immediate stability; however, high complication and failure rates involving revision and deep infection impact its success. In a large study reported by Toepfer et al. showed that over an average of 86-month follow-up, 75 out of 82 patients with a distal femur replacement developed complications with an overall failure rate of 64.6% [18]. Another study by Campbell et al. reported that over an average of 18 month follow-up, 55 patients, 18%

developed aseptic loosening with an overall complication rate of 24% [20]. Wyles et al. reported with a mean follow-up of 5 years the reported complication rates of aseptic loosening, all-cause revision, and reoperation were 17%, 27.5%, and 46.3% respectively, with the overall conclusion and re-confirmation that DFR should remain a salvage option as the final reconstructive option [21]. Additionally, DFR have shown significantly less functional outcomes [11], and, hence, is not ideal in relatively young patients.

The rIMN combined with a locked plating system provides adequate fixation and union which has been shown to translate to improved patient outcomes and quicker return to function [11,13]. Liporace et al. reported 14 out of 14 patients with a distal femur fracture, 9 of which were periprosthetic distal femur fractures, that underwent nail-plate combination remained ambulatory post-operatively. While 8/14 lost level of independence, 5 patients remained independent. Of note, the 5 patients that remained independent were all native distal femur fractures [14]. Biomechanical studies of nail and plate combination have demonstrated that it is more resistant to failure in axial and torsional load tests compared to locked plating or rIMN alone [15,16]. Theoretically with the rIMN, the weight-bearing axis is shifted medially, aligned with the anatomical axis of the femur while the lateral plate adds stability. This is believed to distribute energy evenly between the bone and implants [14]. Increased mechanical strength allows for earlier mobilization and return to function [14]. Kanabur et al. reported on 8 patients treated with dual implant ORIF that did not require revision surgery for refracture, nonunion, or malunion [17]. A disadvantage with this approach includes the use of

additional hardware increasing the cost of surgery, risk of iatrogenic damage to surrounding tissues, and lack of satisfactory distal fixation; however, this case report demonstrates a satisfactory patient outcome. Further studies should be performed to evaluate whether these benefits outweigh the aforementioned disadvantages.

CONCLUSION

Early reported experiences with the combined use of the nail/plate combination in fixation for distal femoral fractures have been encouraging. We believe our report highlights the potential of this technique in highly comminuted periprosthetic fracture situations with extremely limited amounts of distal bone. In circumstances where the long-term functional risks of distal femoral replacement are high, we recommend consideration of this treatment approach.

REFERENCES

[1] Naut A, Ristevski B, Bégué T, Schemitsch EH Periprosthetic Distal Femur Fractures: Current Concepts, *J Orthop Trauma* 2011;25:S82-5.

[2] Lunenfeld B, Stratton P. The clinical consequences of an ageing world and preventive strategies. *Best Pract Res Clin Obstet Gynaecol.* 2013;27(5):643-59.

[3] Kurtz S, Ong K, Lau E, Mowat F, Halpern M. Projections of primary and revision hip and knee arthroplasty in the United States from 2005 to 2030. *J Bone Joint Surg Am* 2007;89(4):780-5.

[4] Singh JA, Yu S, Chen L, Cleveland JD. Rates of Total Joint Replacement in the Unit-

ed States: Future Projections to 2020-2040 Using the National Inpatient Sample. *J Rheumatol* 2019;46(9):1134-40.

[5] Marino DV, Mesko DR. Periprosthetic Distal Femur Fracture. In: StatPearls [Internet]. Treasure Island (FL): StatPearls Publishing; 2021 Jan-. At: <https://www.ncbi.nlm.nih.gov/books/NBK554439/>.

[6] Canton G, Ratti C, Fattori R, Hoxhaj B, Murena L. Periprosthetic knee fractures. A review of epidemiology, risk factors, diagnosis, management and outcome. *Acta Biomed.* 2017;88(2S):118-28.

[7] Quinzi DA, Childs S, Lipof JS, Soin SP, Ricciardi BF. The Treatment of Periprosthetic Distal Femoral Fractures After Total Knee Replacement, *JBJs Reviews* 2020;8(9):e20.00003.

[8] Ricci WM. Periprosthetic femur fractures. *J Orthop Trauma* 2015;29(3):130-7.

[9] Angers-Goulet M, Pelet S, Belzile EL, Bédard M. Total Knee Arthroplasty with Distal Femoral Replacement is Associated with an Important Complication Rate. A Case Series. *Knee* 2019;26(5):1080-7.

[10] Hart GP, Kneisl JS, Springer BD, Patt JC, Karunakar MA. Open Reduction vs Distal Femoral Replacement Arthroplasty for Comminuted Distal Femur Fractures in the Patients 70 Years and Older. *J Arthroplasty.* 2017;32(1):202-6.

[11] Darrith B, Bohl DD, Karadsheh MS, Sporer SM, Berger RA, Levine BR. Periprosthetic Fractures of the Distal Femur: Is Open Reduction and Internal Fixation or Distal Femoral Replacement Superior? *J Arthroplasty.* 2020;35(5):1402-16.

- [12] Jassim SS, McNamara I, Hopgood P. Distal Femoral Replacement in Periprosthetic Fracture Around Total Knee Arthroplasty. *Injury* 2014;45(3):550-3.
- [13] Yoon RS, Patel JN, Liporace FA. Nail and Plate Combination Fixation for Periprosthetic and Interprosthetic Fractures. *J Orthop Trauma* 2019;33(Suppl 6):S18-20.
- [14] Liporace FA, Yoon RS. Nail Plate Combination Technique for Native and Periprosthetic Distal Femur Fractures. *Journal of Orthopaedic Trauma* 2019;33(2):e64-e68.
- [15] Chen SH, Tai CL, Yu TC, Wang CW, Lin CW, Chen CY, Liu KC. Modified fixations for distal femur fractures following total knee arthroplasty: a biomechanical and clinical relevance study. *Knee Surg Sports Traumatol Arthrosc* 2016;24(10):3262-71.
- [16] Başcı O, Karakaşlı A, Kumtepe E, Güran O, Havıtcıođlu H. Combination of Anatomical Locking Plate and Retrograde Intramedullary Nail in Distal Femoral Fractures: Comparison of Mechanical Stability. *Eklem Hastalik Cerrahisi* 2015;26(1):21-6.
- [17] Kanabur P, Sandilands SM, Whitmer KK, Owen TM, Coniglione FM, Shuler TE. Nail and Locking Plate for Periprosthetic Fractures. *J Orthop Trauma* 2017;31(12):e425-e431.
- [18] Toepfer A, Harrasser N, Schwarz PR, Pohlig F, Lenze U, Mühlhofer HML, Gerdesmeyer L, von Eisenhart-Rothe R, Suren C. Distal Femoral Replacement with the MML system: A Single Center Experience with an Average Follow-up of 86 months. *BMC Musculoskelet Disord* 2017;18(1):206.
- [19] Thompson SM, Lindisfarne EA, Bradley N, Solan M. Periprosthetic Supracondylar Femoral Fractures above a Total Knee Replacement: Compatibility Guide for Fixation with a Retrograde Intramedullary Nail. *J Arthroplasty* 2014;29(8):1639-41.
- [20] Campbell ST, Lim PK, Kantor AH, Gausden EB, Goodnough LH, Park AY, Bishop JA, Achor TS, Scolaro JA, Gardner MJ. Complication Rates after Lateral Plate Fixation of Periprosthetic Distal Femur Fractures: A Multicenter Study. *Injury* 2020;51(8):1858-62.
- [21] Wyles CC, Tibbo ME, Yuan BJ, Trousdale RT, Berry DJ, Abdel MP. Long-Term Results of Total Knee Arthroplasty with Contemporary Distal Femoral Replacement. *J Bone Joint Surg Am* 2020;102(1):45-51.