

## CASE REPORT

# Gross Trunnion Failure in Recalled Femoral Head in Total Hip Arthroplasty

Gavin Mills, MD<sup>1</sup>; Lydia Kore, MD<sup>1</sup>; Jason Beachler, MD<sup>2</sup>; Bryan Kaiser, MD<sup>3</sup>

<sup>1</sup>Department of Orthopaedics, San Antonio Military Medical Center; Fort Sam Houston, TX, USA

<sup>2</sup>Wright-Patterson Medical Center; Wright Patterson Air Force Base, OH, USA

<sup>3</sup>The San Antonio Orthopaedic Group; San Antonio, TX, USA

## ABSTRACT

Several relatively uncommon complications of total hip arthroplasty drive the current practice of orthopaedic surgeons given the significant morbidity associated with failed joint replacement. Among these rare but substantial complications is gross trunnion failure (GTF) whereby the modular head loosens and dissociates from the monoblock femoral stem/trunnion. GTF has been reported across several implant manufacturers, most recently, with the Stryker Low Friction Ion Treatment V40 Femoral Head. These implants were subsequently recalled in August of 2016 for concerns of the taper lock failure on the trunnion leading to head dissociation in some cases. In this case report, we describe a case of unilateral GTF in a patient who received bilateral recalled Stryker total hip arthroplasty implants. .

**Level of Evidence:** V; Case report.

**Keywords:** Total hip arthroplasty; Implant recall; gross trunnion failure; Metallosis.

## INTRODUCTION

Several relatively uncommon complications of total hip arthroplasty (THA) drive the current practice of orthopaedic surgeons given the significant morbidity associated with failed joint replacement. Among these rare but substantial complications is gross trunnion failure (GTF) whereby the modular head loosens and dissociates from the

monoblock femoral stem/trunnion. GTF has been reported across several implant manufacturers, most recently, with the Stryker Low Friction Ion Treatment V40 Femoral Head. These implants were subsequently recalled in August of 2016 for concerns of the taper lock failure on the trunnion leading to head dissociation in some cases.

Given that the U.S. Food and Drug Administration estimates that over 42,000 of the recalled implants are in commerce, orthopaedic surgeons must be aware of the signs, symptoms and necessary treatment protocol for patients suspected to have GTF. In this case report, we describe a case of

### Corresponding Author:

Capt. Gavin Mills, MD

Department of Orthopaedics  
San Antonio Military Medical Center  
3551 Roger Brooke Dr  
Fort Sam Houston, TX 78234, USA  
e-mail: c13gavin.mills@gmail.com

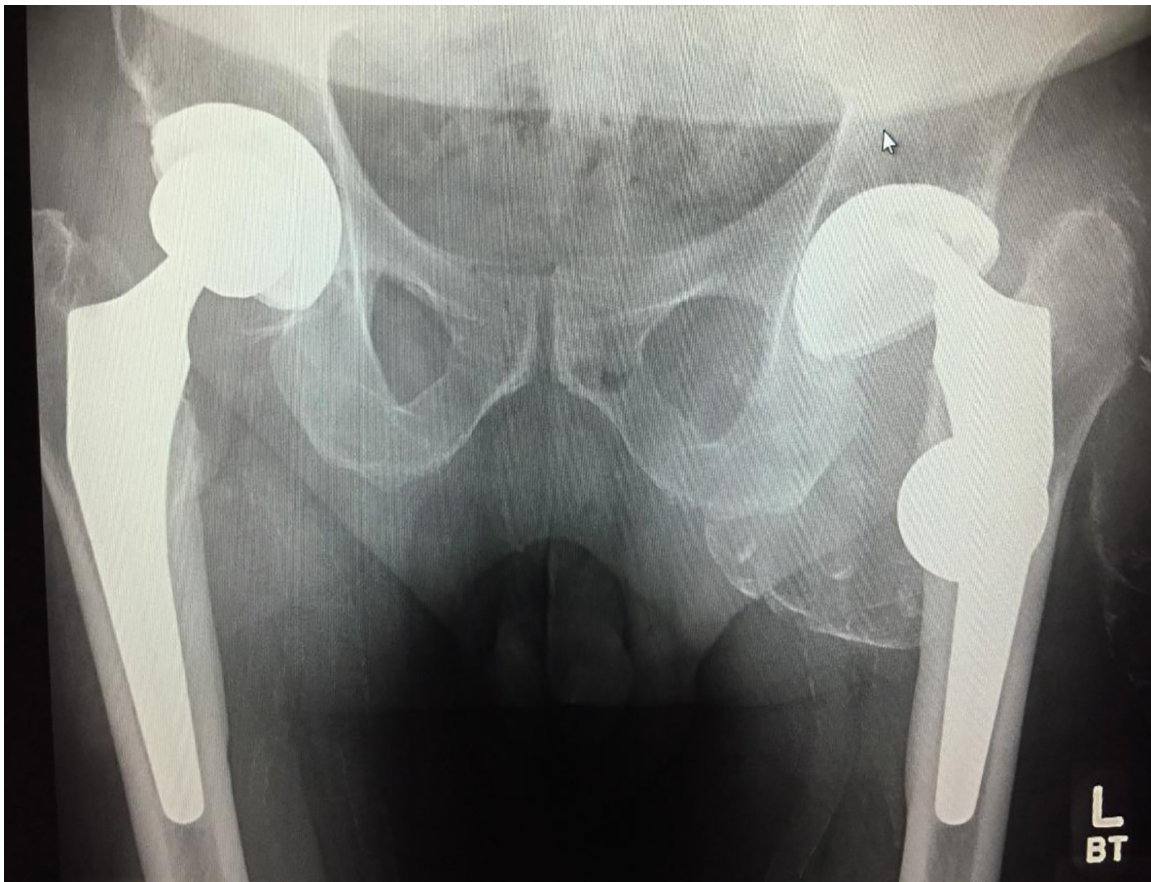
unilateral GTF in a patient who received bilateral recalled Stryker total hip arthroplasty (THA) implants. The patient underwent revision THA on the presenting side and after further workup, the patient was found to have signs of impending GTF on the contralateral side. The complications were identified, and the patient was subsequently indicated for sequential bilateral revision THA.

### CASE PRESENTATION

The patient is an 81-year-old male with a chief complaint of left hip pain for three weeks notable for grinding and crepitus. Ten years prior, the patient was diagnosed with bilateral hip and knee osteoarthritis and underwent left total hip arthroplasty (THA)

in August 2007 and right THA in February 2008. Stryker Low Friction Ion Treatment (LFIT) V40 implants were used in both operations. Subsequent radiographic work up at present time, demonstrated left femoral head dissociation from the trunnion with extensive trunnionosis as well as metallosis surrounding his left hip (Figure 1). On exam, patient was found to have painful range of motion about his left hip as well as grinding and crepitus. His left leg was found to be 1 cm shorter than the right.

The patient underwent left hip THA revision August 2017. The hip was approached through an anterolateral incision. Upon entering the joint space, a metal-stained joint fluid was encountered with notable fretting about the trunnion

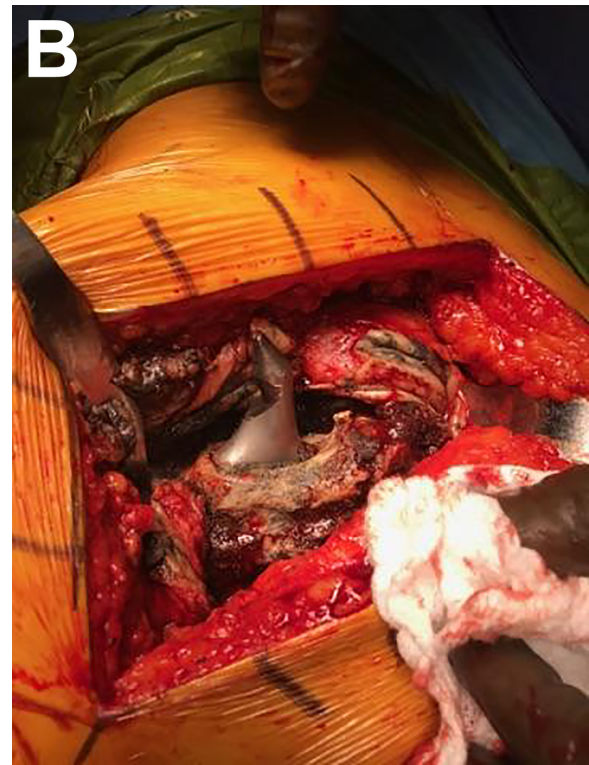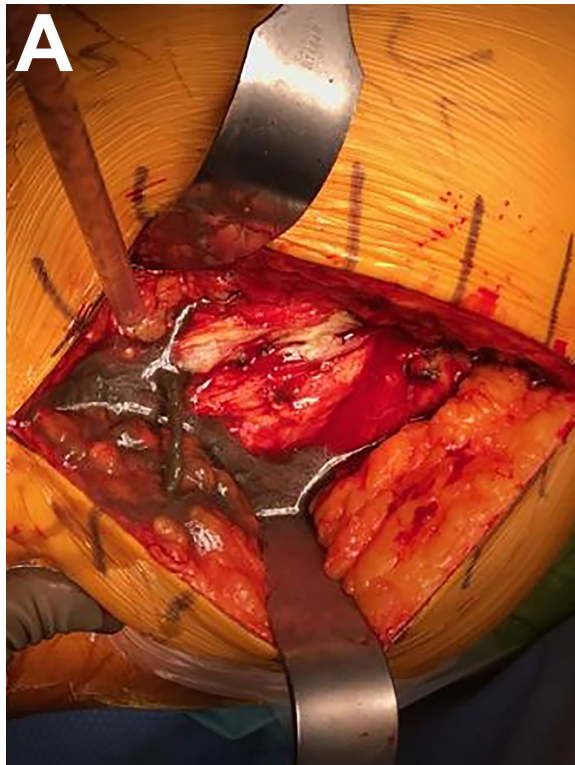


**Figure 1.** Plain radiograph demonstrating left femoral head dissociation from the trunnion with extensive trunnionosis as well as metallosis surrounding his left hip.

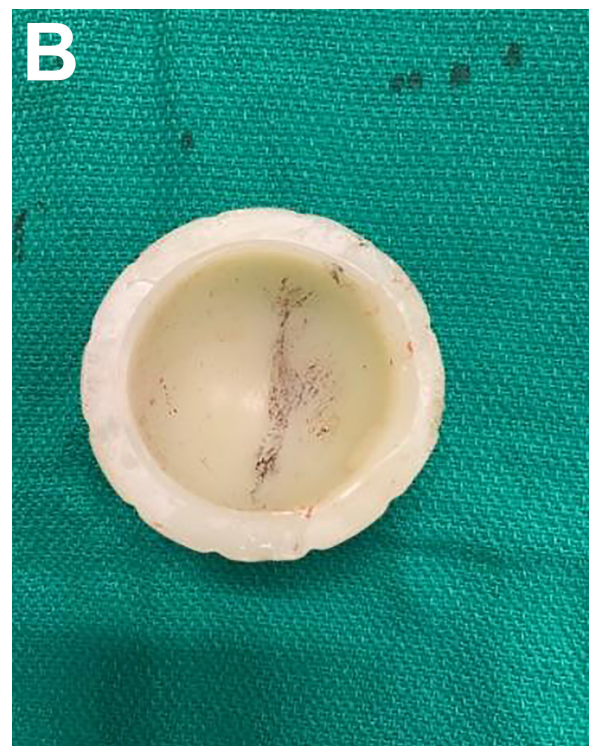
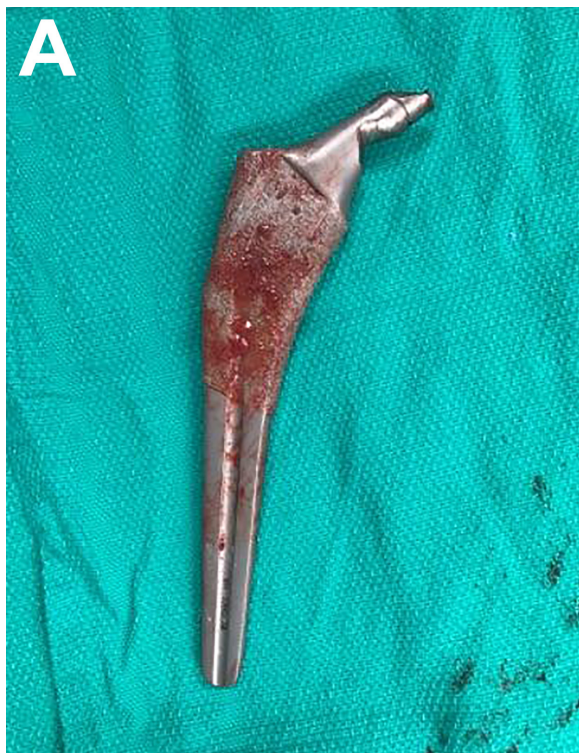
and significant damage to the acetabular liner (Figure 2 and 3). The femoral head was lo-

calized and removed. Additionally, there was extensive metallosis over the anterior and

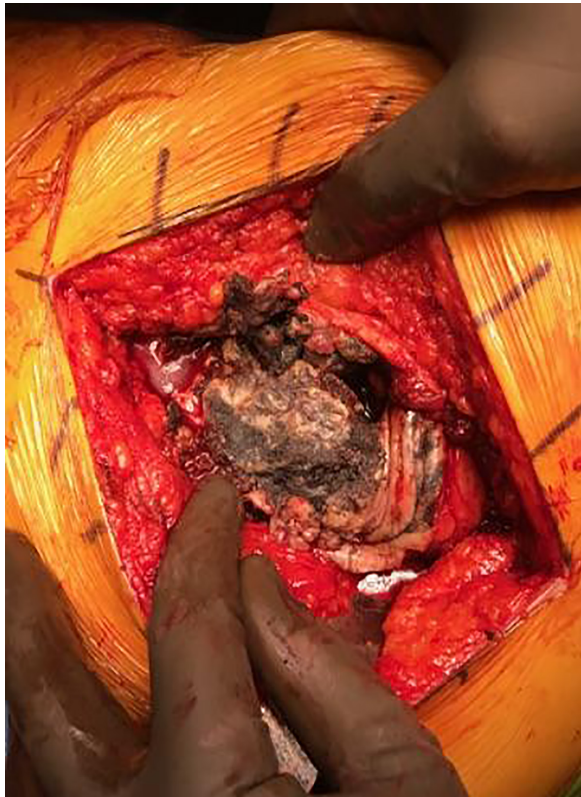


**Figure 2.** Intraoperative images revealing metal-stained fluid (A) and issue around the trunnion (B) consistent with metallosis.



**Figure 3.** Retrieved THA components demonstrated notable fretting about the trunnion (A) and a significant damage to the acetabular liner (B)





**Figure 4.** Extensive metallosis around the hip capsule.

and lateral two-thirds of the hip capsule rendering the abductors incompetent (Figure 4). The patient's construct was revised using a constrained liner, the addition of two 6.5-mm dome screws as well as a size 13 lateralized cemented stem and a 28 mm standard head.

The patient recovered as expected. After finding large areas of fluid collection around the right hip on Magnetic Resonant Imaging (MRI) consistent with trunnionosis, he underwent right THA as well. The patient's postoperative course has been, thus far, uncomplicated and he is expected to make a full recovery. This case represents the first known published case of this complication in the state of Texas.

## DISCUSSION

Gross trunnion failure is a rare but serious

complication of THA seen at an increased rate with this subset of recalled Stryker implants. Given that the U.S. Food and Drug Administration estimates that over 42,000 of the recalled implants are in commerce, orthopaedic surgeons must be aware of the signs, symptoms and necessary treatment protocol for patients suspected to have GTF. Many patients with GTF are initially asymptomatic until an acute exacerbation of pain and inability to bear weight while others report clicking for the weeks prior to catastrophic failure. Several authors have explored methods of detecting impending implant failure. Urish et al. describe a series of 30 patients with trunnion failures ranging from head-neck taper corrosion leading to adverse local tissue reaction (ALTR) and metallosis to GTF [1]. The most worrisome finding in this study was that only half of the patients in their series were from recalled implants. Variables found to increase the risk of impending implant failure where high offset angle of 127 degrees neck angle femoral stems, increased femoral neck offset, slight oblique angle between the femoral head and neck taper on radiograph, faint radiodensity around the hip capsule, and elevated serum cobalt to chromium ratio. Additionally, these authors advocate image guided joint aspiration with a simple colorimetric assay where black synovial fluid is associated with wear at the trunnion interface necessitating stem replacement whereas brown, grey or straw-colored aspirate suggests head-neck taper corrosion without gross damage to the trunnion. In these cases, an exchange of the modular head and liner is recommended [1].

Magnetic resonance imaging (MRI) has been used to augment diagnostic work-up for patients with concern for metallosis. In a retrospective cohort study, Hauptfleisch

et al. described an MRI classification system that may be predictive of revision arthroplasty. In a series of 33 patients, they found that 90% (10/11) of patients with symptomatic reactive periprosthetic soft tissue masses that were characterized by a solid mass greater than 3 cm required revision arthroplasty. Though there appears to be prognostic value in MRI regarding the need for revision arthroplasty, there remains to be insufficient data to confirm the utility and cost effectiveness of this imaging modality [2].

Tissue histology has been postulated to describe the etiology of associated ALTR routinely seen in THA complicated by metallosis. Ricciardi et al. found that tissue specimens from metal on metal bearing surface implants were composed of macrophage predominant chronic inflammation. The authors theorize this is due to the surface corrosion shedding nanoparticle debris and increases the oxidative stress on macrophages leading to early cell death and necrosis ultimately altering the lubrication of bearing surface and potentially accelerating head neck corrosion. This process may be associated with blood levels of metal ions. Though tissue histology may be helpful determining the cause of ALTR in THA, intraoperative tissue sample remains nonspecific and can be associated with several different etiologies of tissue inflammation [3,4].

Several etiologies have been postulated in GTF. Some authors point to the properties of the cobalt chromium alloy (CoCr) used in these implants. Given its resistive properties to wear and corrosion it has become the standard material for modern THA implants [5-7]. However, it has been associated with ALTR and likely head-neck taper corrosion [8,9]. This process likely goes on to cause abrasive wear of the trunnion taper inside the femoral head. Alternatively, if any

loosening occurs at the junction of the modular components, crevice corrosions may also cause detrimental mechanical failure of the implant [1]. In the case of our patient's recalled implants, the metal head was milled with a morse taper slightly too large for the trunnion. This resulted in micromotion between implants and ultimate fretting until catastrophic failure.

In an effort to decrease the sequelae of ALTR, many advocate for the use of ceramic femoral heads [1]. Studies show the majority of material loss from fretting corrosion occurs from the CoCr femoral head bore. When compared to using a ceramic femoral head, CoCr produces a significantly higher level of systemic metal release. Additionally, there is less fretting and corrosion from the stem component when a ceramic femoral head is used [11]. Surgeons must consider these advantages to CoCr alternatives when selecting prostheses.

## CONCLUSIONS

In conclusion, orthopaedic surgeons must be ever vigilant of the clinical signs of ALTR and GTF and be equally prepared to obtain the necessary studies to diagnosis and treat them. Given the prevalence of recalled prostheses currently in the U.S. population, as well as the potential for non-recalled implants to be associated with GTF, these diagnoses must be considered in the differential for symptomatic THA. Serum metal ion levels, radiographs, MRI and black synovial fluid obtained from hip aspirate are all helpful in diagnosing ALTR and impending GTF.

## REFERENCES

- [1] Urish KL, Hamlin BR, Plakseychuk AY,

Levison TJ, Higgs GB, Kurtz SM, DiGioia AM. Trunnion failure of the recalled low friction ion treatment cobalt chromium alloy femoral head. *J Arthroplasty* 2017;32:2857-63.

[2] Hauptfleisch J, Pandit H, Grammatopoulou G, Gill HS, Murray DW, Ostlere S. A MRI classification of periprosthetic soft tissue masses (pseudotumours) associated with metal-on-metal resurfacing hip arthroplasty. *Skeletal Radiol* 2012;41:149-55.

[2] [Hauptfleisch J, Pandit H, Grammatopoulos G, Gill HS, Murray DW, Ostlere S. A MRI classification of periprosthetic soft tissue masses (pseudotumours) associated with metal-on-metal resurfacing hip arthroplasty. *Skeletal Radiol* 2012;41:149-55.

[3] Ricciardi BF, Nocon AA, Jerabek SA, Wilner G, Kaplowitz E, Goldring SR, Purdue PE, Perino G. Histopathological characterization of corrosion product associated adverse local tissue reaction in hip implants: a study of 285 cases. *BMC Clin Pathol* 2016;16:3.

[4] Liow MH, Urish KL, Preffer FI, Nielson GP, Kwon YM. Metal ion levels are not correlated with histopathology of adverse local tissue reactions in taper corrosion of total hip arthroplasty. *J Arthroplasty* 2016;31:1797-802.

[5] Kolb A, Grubl A, Schneckener CD, Chiari C, Kaider A, Lass R, Windhager R. Cementless total hip arthroplasty with the rectangular titanium Zweymuller stem: a concise follow-up, at a minimum of twenty years, of previous reports. *The Journal of bone and joint surgery American volume* 2012;94:1681-4.

[6] Corten K, Bourne RB, Charron KD, Au K, Rorabeck CH. Comparison of total hip arthroplasty performed with and without cement: a randomized trial. A concise follow-up, at twenty years, of previous reports. *J Bone Joint Surg Am* 2011;93:1335-8.

[7] Makela KT, Eskelinen A, Pulkkinen P, Paavolainen P, Remes V. Total hip arthroplasty for primary osteoarthritis in patients fifty-five years of age or older. An analysis of the Finnish arthroplasty registry. *J Bone Joint Surg Am* 2008;90:2160-70.

[8] Cooper HJ, Della Valle CJ, Berger RA, Tetreault M, Paprosky WG, Sporer SM, Jacobs JJ. Corrosion at the head-neck taper as a cause for adverse local tissue reactions after total hip arthroplasty. *J Bone Joint Surg Am* 2012;94:1655-61.

[9] McGrory BJ, MacKenzie J, Babikian G. A high prevalence of corrosion at the head-neck taper with contemporary Zimmer non-cemented femoral hip components. *J Arthroplasty* 2015;30:1265-8.

[10] Kocagoz SB, Underwood RJ, MacDonald DW, Gilbert JL, Kurtz SM. Ceramic heads decrease metal release caused by Head-taper fretting and corrosion. *Clin Orthop Relat Res* 2016;474:985-94.

[11] Kurtz SM, Kocagoz SB, Hanzlik JA, Underwood RJ, Gilbert JL, MacDonald DW, Lee GC, Mont MA, Kraay MJ, Klein GR, Parvizi J, Rimnac CM. Do ceramic femoral heads reduce taper fretting corrosion in hip arthroplasty? A retrieval study. *Clin Orthop Relat Res* 2013;471:3270-82.